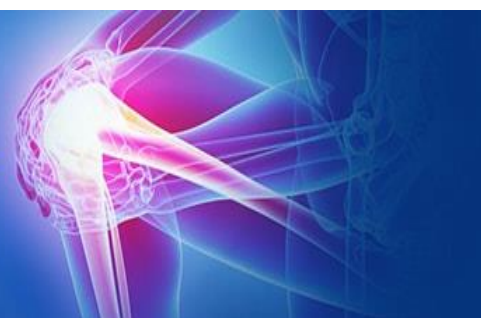



ISSN (P): 2521-3466
ISSN (E): 2521-3474
© Clinical Orthopaedics
www.orthoresearchjournal.com
2020; 4(1): 113-118
Received: 24-11-2019
Accepted: 28-12-2019

Dr. JJ Patwa
MS (Ortho) Ex. Professor and
H.O.D., Chief Restoknee
Surgeon, Restoknee Healthcare
Pvt. Ltd., 1st floor, Ashirwad
Avenue, Opp. Kocharab Ashram,
Paldi, Ahmedabad, Gujarat,
India

Dr. Takshay J Gandhi
MS (Ortho) Gold Medalist,
Restoknee Healthcare Pvt. Ltd.,
1st floor, Ashirwad Avenue, Opp.
Kocharab Ashram, Paldi,
Ahmedabad, Gujarat, India

Dr. Savan Patel
Full Time Physiotherapist,
Restoknee Healthcare Pvt. Ltd.,
1st floor, Ashirwad Avenue, Opp.
Kocharab Ashram, Paldi,
Ahmedabad, Gujarat, India

Dr. Swapni Bhatt
Chief Administrative Officer,
Restoknee Healthcare Pvt. Ltd.,
1st floor, Ashirwad Avenue, Opp.
Kocharab Ashram, Paldi,
Ahmedabad, Gujarat, India

Corresponding Author:
Dr. JJ Patwa
MS (Ortho) Ex. Professor and
H.O.D., Chief Restoknee
Surgeon, Restoknee Healthcare
Pvt. Ltd., 1st floor, Ashirwad
Avenue, Opp. Kocharab Ashram,
Paldi, Ahmedabad, Gujarat,
India

Alternating view in controversial treatment of osteoarthritis of knee (Restoknee vs TKR)

Dr. JJ Patwa, Dr. Takshay J Gandhi, Dr. Savan Patel and Dr. Swapni Bhatt

DOI: <https://doi.org/10.33545/orthor.2020.v4.i1b.210>

Abstract

The osteoarthritis of knee is a wide spread condition worldwide and specially in country like India where the routine life is such where knee joint arthritis occurs at an early age. The widely used treatment option for knee arthritis is total knee replacement which have its own complication and once the complication like infection sets in we are left with nothing but to do arthrodesis or revision knee after controlling infection which cause a lot of problem for the patient as well as doctors. And moreover if total knee replacement done at an early age predisposes the patient to revision surgery as the life of the joint used is not more than life expectancy of the patient this puts a surgical toll over patient as well as financial load. Here we have compared our technique of treating osteoarthritis wherein we are preserving the natural joint and no implant are used in our technique which in itself reduced the major complications and even if by any chance complication occurs we are left with many options to give functional knee to the patient rather than going for arthrodesis which is not very well accepted by many patients. In this article we have compared pros and cons of our technique with total knee replacement.

Keywords: controversial view in treatment of OA knee

Introduction

In current scenario osteoarthritis of knee is mainly treated by total knee replacement because of familiarity of the implant mechanics and relatively easily reproducible procedure with good to excellent result and thus it is propagated by many doctors but it being a replacement surgery has its shortcoming and varied complications such as patient in india usually sit crosslegged and squat for most of their daily activity and if they want to play sports or do any other activity after total knee replacement they have to limit themselves for the longevity of the joint or else they have to undergo replacement surgery earlier which again exposes the patient to second surgery which cost more than the primary knee replacement and again it has its own complication and limitations. Moreover in modern society it has become a status symbol for certain patients and now a days even gold implants are available for total knee replacement. Thus knee preservation has been avoided for quite a long time which has many benefits over total knee replacement with good to excellent results.

To overcome this problem and give patient a knee he/she would enjoy in all his/her routines as well as fulfil his/her hobbies limitation free and most importantly pain free we have devised a surgery in which we are preserving the original knee joint in which patient can even play football if one desires to. Moreover in the restoknee technique of knee preservation surgery we do not put any type of implant or foreign body in the knee. The procedure is mainly based on the principle of very old and established technique of closed wedge osteoclasia. This itself reduces the varied complication that comes handy with a radical procedure like total knee replacement.

Do you know what is ideal AP view of knee joint?

For true AP view, X-ray with full weight bearing (Single leg weight bearing), following is the procedure:

1. Person should stand on single leg by flexing and abducting 45° opposite limb and allow full body weight over affected limb.

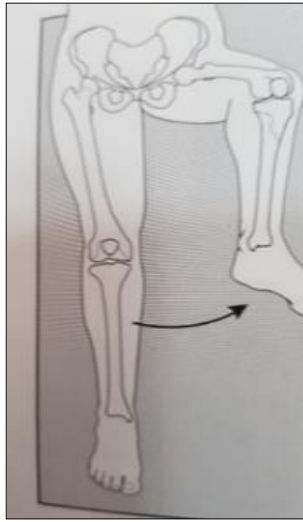

Fig 1: Ideal position of limb with full weight bearing on affected knee for x-ray

2. Patient should remain 305 cm away from the camera. (knee to camera distance should be 305 cm)

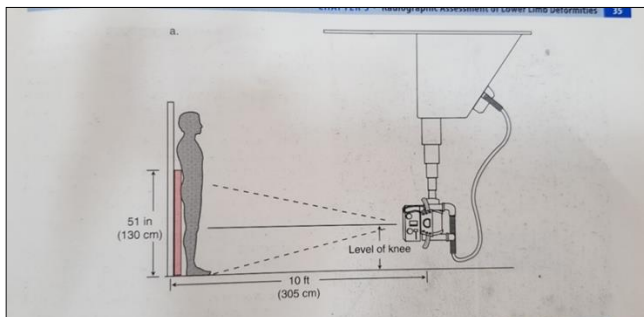


Fig 2: Ideal distance between camera and patient

3. Catch the patella between index finger and thumb and then rotate the foot internally or externally till patella face forward, parallel to camera

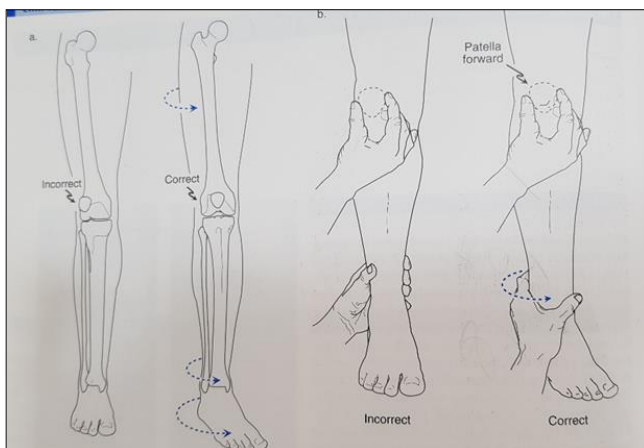


Fig 3: Ideal position of patella before taking x-ray

4. Camera and knee level should be equal
5. Tilt the camera 5° downward as for posterior slope of articular surface of Tibia.

6. Full length film should be kept behind the leg to get proper view. By doing this, the magnification error can be reduced to minimum.
 - By taking the x-ray in this way, you can see real AP view of medial compartment of knee joint.
 - For the help, we are taking other views like lateral view, skyline view, abduction and adduction film (varus and valgus stress) good quality of x-ray.
 - Long view technique is also important to find out angle of deformity.
 - Scanogram
 - High Resolution CT Scan
 - 'Curis Data Science' value is also important for accuracy in pre-operative assessment. (regarding this, we have already published in IJAR ['International Journal of Advanced Research'- 32_IJAR_30004- ISSN: 2320-5407 Res. 7(12), page no. 633 to 640])

To what we say false?

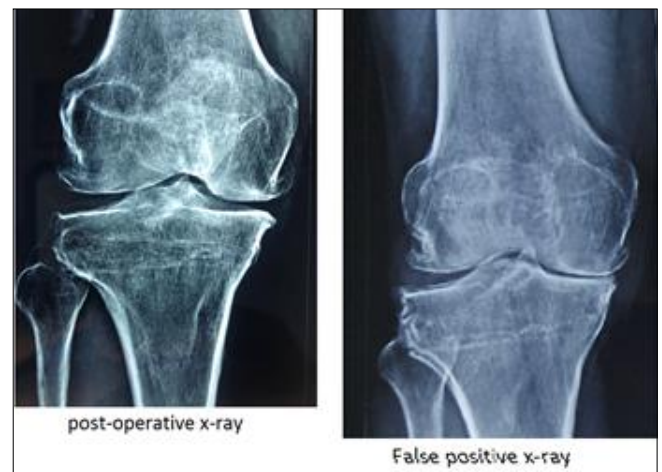

Fig 4: Real post operative x-ray Vs false positive x-ray

In above picture, our operated case, post-operative x-ray proper AP x-ray at follow up which is found normal. The same leg, same patient x-ray was taken outside improperly suggesting medial compartment syndrome even though patient had good range of movement without pain, who was advised outside for Total Knee Replacement by this false x-ray.

- Position of the patient.
- Knee to camera distance
- Mal rotation of foot
- Patellar condition (position of patella)
- Mal tilt of camera
- Hip mal formation causing difference in neck shaft anteversion of femur and tibia like enchondromata or intra articular injury.

These are the conditions, you are likely to get unusual findings of knee joint to suggest failure of restoknee surgery. Because at times, it looks like narrowing of medial compartment, so in such cases, clinical examination of patient and his/ her knee joint is very important. If x-ray showing changes of osteoarthritis because of false, by x-ray patients are advised to undergo for Total Knee Replacement, it is a crime. If patient is having false x-ray reading but having full range of movements, walking distance (claudication) and standing capacity are good, then one should try to get proper AP view. If he can't, then subject the patient for arthroscopy to see actual condition or lesion in the

medial joint space articular surface than to decide for arthroplasty. It is better to tackle rather than his/her false x-ray.

Here are few examples (five cases) of our technique, where they got advice for arthroplasty by outsiders.

Cases
Case 1

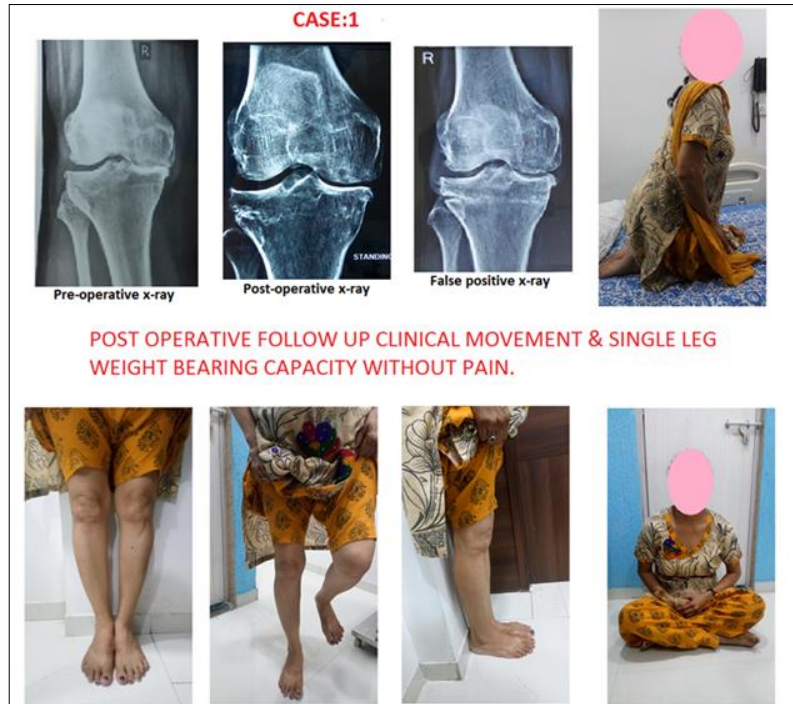

Fig 5: Case 1

Pre-operative findings: Bilateral knee pain with narrowing of medial compartment in both knees, throbbing type of pain at medial side of knee joint, restriction of floor sitting and cross legged sitting, walking distance restricted upto few steps and could not able to climb up stairs, standing time restricted to few minutes.

Post-operative findings: No knee pain, knee restored to its original position, no throbbing pain, patient able to sit on floor without pain, can sit with cross legs, walking distance 4 km at a time, standing time improved upto 45 min at a time. Patient is able to climb upstairs without support.

Case 2

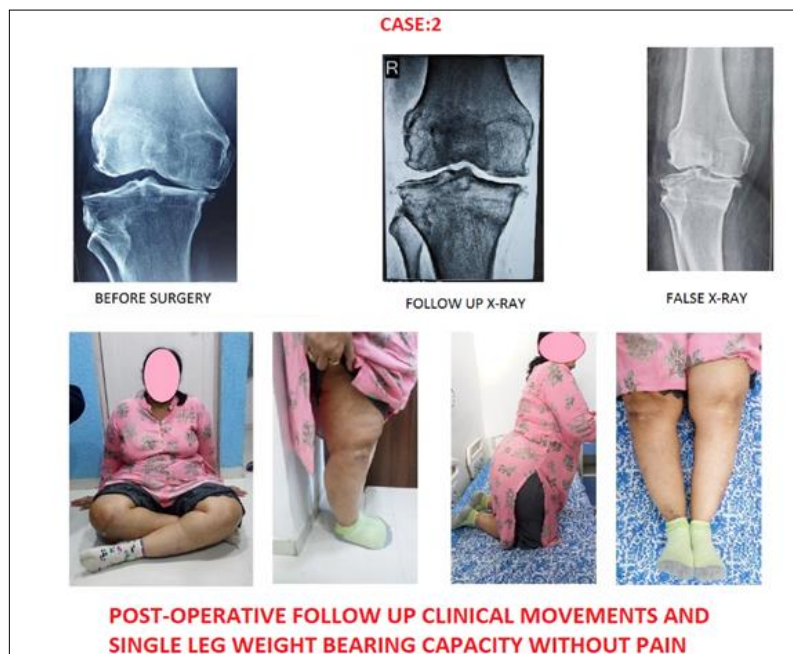


Fig 6: Case 2

Pre-operative findings: Obesity, Bilateral knee pain (Right knee>left knee) with narrowing of medial compartment, C/o locking and of knees with painful and waddling gait, 8° Fixed Flexion Deformity in right knee, throbbing pain at night, morning stiffness of right knee, narrowing of medial joint space of right knee, walking distance restricted upto few steps only, standing time 3-5 minutes, climbing up and down stairs was restricted due to pain, floor sitting was difficult, could sit with cross legs on bed.

Post-operative findings: no right side knee pain, no morning stiffness, no Fixed Flexion Deformity in right knee, limping gait because of left knee OA, right side medial space opened up, able to sit on floor and with cross legs on floor, can now climb up and down stairs without pain in right knee, walking distance increased upto 700-800 meters, standing time increased upto 30 minutes.

Case 3

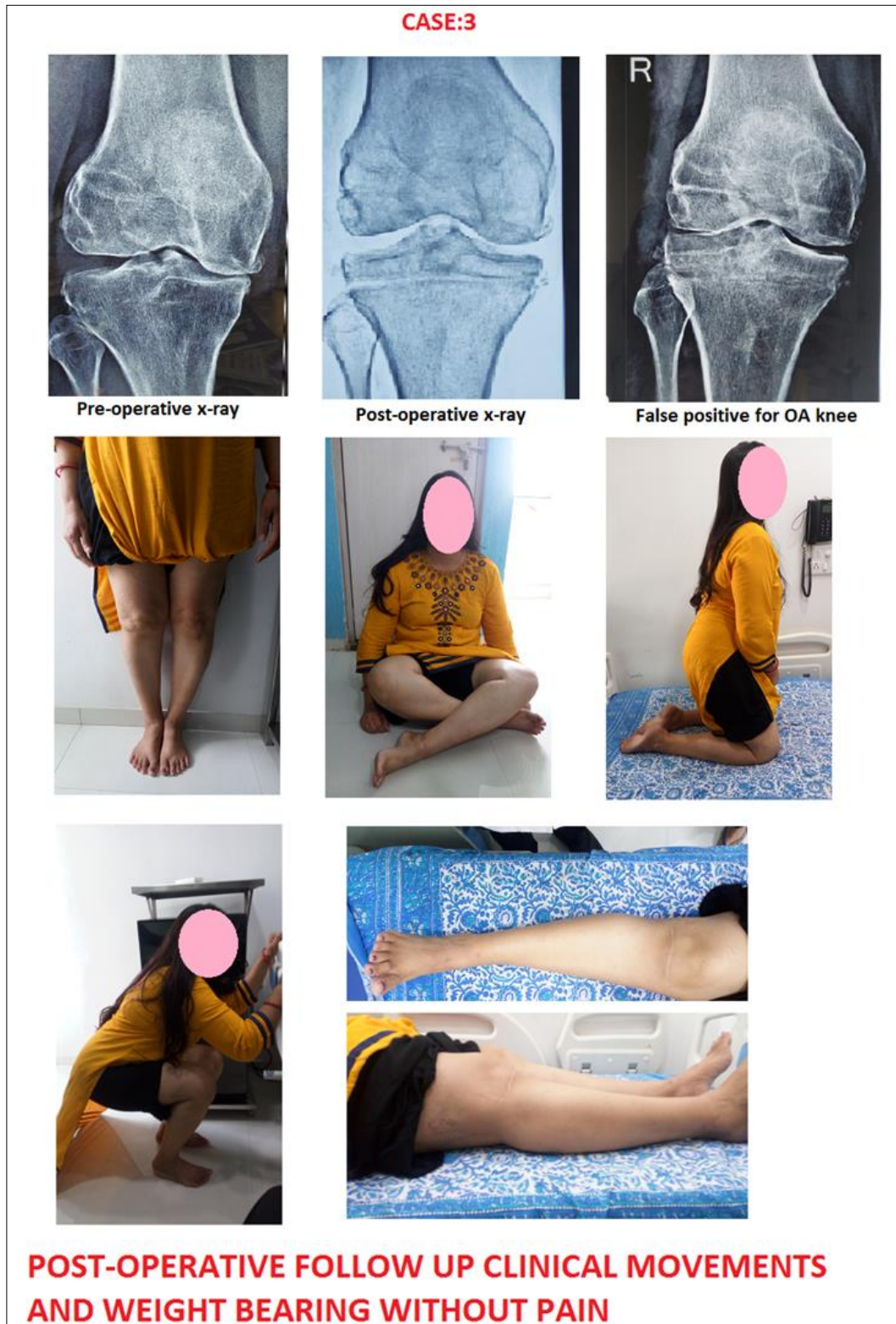

Fig 7: Case 3

Pre-operative findings: bilateral knee pain with swelling (right>left), disturbed sleep due to pain, with morning stiffness in right knee, crepitations in right knee while extension and flexion of right knee. Narrowing of medial compartment with OA changes (right>left), difficulty in sitting on floor, patient could not step up and down stairs, standing time was reduced upto 5-8 minutes at a time and walking distance was reduced upto 10-20 meters.

Post-operative findings: no pain in right knee, no crepitations, morning stiffness not there, walking distance increased upto 1.5 km, then left knee pain starts with limping but no pain in right knee, can sit on floor with cross legs for Pooja for 40 minutes at a time, can climb up and down stairs without support 15 steps at a time.

Case 4

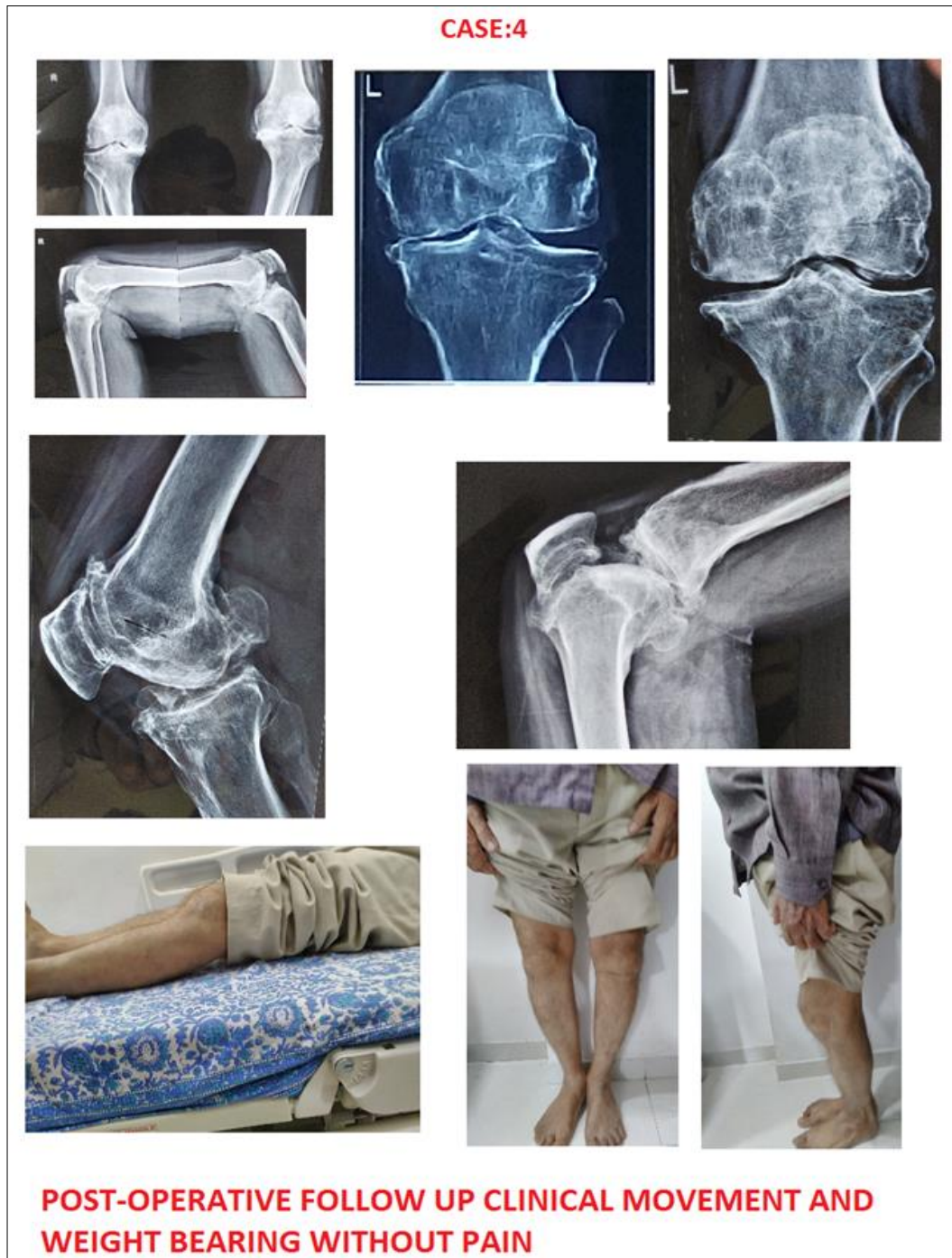

Fig 8: Case 4

Pre-operative findings: bilateral knee pain with 14° Fixed Flexion Deformity, varus knee (left>right), due to throbbing at rest- disturbed sleep, crepitations during flexion, bilateral narrowing of medial space, restriction of knee flexion and extension, walking distance reduced upto 30 meters, standing time reduced upto 5 minutes at a time. Patient could not able to sit with cross legs and on floor.

Post-operative findings: no pain in left knee, no throbbing pain, no crepitations in left knee, left medial space opened up, full flexion of left knee, able to sit on floor and with cross legs, walking distance increased upto 500 meters then pain occurs in right knee, standing time increased upto 30 minutes at a time, now able to travel in bus and car for a longer distance.

Case 5

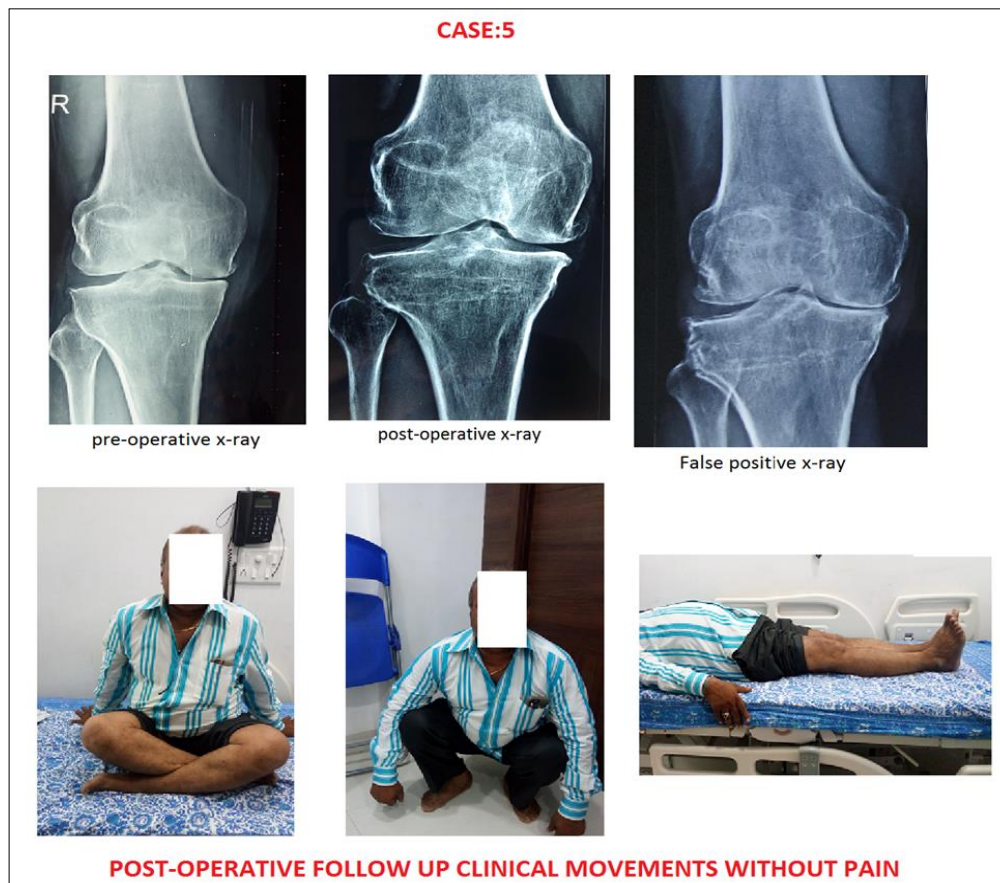

Fig 9: Case 5

Pre-operative findings: Right leg posterior pulling pain, knee pain with 10° Fixed Flexion Deformity, right knee locking during walking occasionally, narrowing of medial space of right knee, because of pain, he cannot able to walk more than 20 meters, cross-legged sitting and floor sitting was difficult and stair climbing was painful with support. Patient owns a garage and was not able to squat because of right knee osteoarthritis, also had restricted range of motion.

Post-operative findings: After restoknee surgery, no pain, no knee locking while walking, walking distance increased upto 3-4 km at a time without pain, patient is able to sit on floor and with crossed legs, can squat also, patient can also climb up and down stairs without support also (40-50 steps at a time).

We have gone through our all operated cases from 1997 to 2019, we found in 5% cases such indices happened, the patient is advised to undergo for arthroplasty in spite of restoknee surgery and patient has refused to undergo for re-surgery (Total Knee Replacement), this encouraged us to prepare this paper.

Conclusion

So we concluded that to take decision on false, it is better to take decision on clinical examination and correlate with properly taken x-ray or other assessment data for re-surgery. In our follow up cases 5% were advised to undergo for Total Knee Replacement by "false" x-rays.

References

1. Non-replacement of OA knee- International Journal of Orthopaedics Sciences- by Dr. JJ Patwa, Dr. Savan Patel.
2. Different surgical options for monocompartmental

osteoarthritis of the knee: high tibial osteotomy versus unicompartmental knee arthroplasty versus total knee arthroplasty: indications, techniques, results, and controversies.

3. Mont MA1, Stuchin SA, Paley D, Sharkey PF, Parvisi J, Tria AJ Jr, Bonutti PM *et al.* high tibial osteotomy versus unicompartmental knee arthroplasty for medial compartment arthrosis of the knee: a review of the literature
4. Federico Dettoni MD, Davide Edoardo Bonasia MD, Filippo Castoldi MD, Matteo Bruzzone MD, Davide Blonna MD, Roberto Rossi MD. Knee X-Ray Image Analysis Method for Automated Detection of Osteoarthritis.
5. Lior Shamir, Shari M Ling, William W Scott Jr, Angelo Bos, Nikita Orlov, Tomasz J Macura *et al.* Ahlback, Osteoarthritis of the knee: A radiographic investigation, *Acta Radiol. Suppl.* 1968; 277:7-72.
6. Radiographic image analysis in the study of bone morphology, *Clin. Phys. Physiol. Meas.* 1987; 8:105-121.
7. Buckwalter HJ Mankin. Instructional course lectures the American Academy of Orthopaedic Surgeons Ñ Articular Cartilage. Part II: Degeneration and osteoarthritis repair regeneration and transplantation, *J Bone Joint Surg.* 1997; 79:612-632.
8. Kellgren JH, Lawrence JS. Radiologic assessment of osteoarthritis, *Ann. Rheum. Dis.* 1957; 16:494-501.
9. Nottingham health profile assessment of health-related quality of life in primary knee osteoarthritis patients: Relation to clinical features and radiologic score.
10. Nawito ZO, El-Azkalany GS, El-Sayad M. The Egyptian Rheumatologist, 2018.